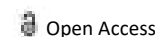




COMMENTARY



Frozen Section Procedure in Tissue Processing

Farah Hamza*

Department of Histology, University of Kairouan, Kairouan, Tunisia

Description

The frozen section procedure is a pathological laboratory rapid microscopic analysis of a specimen is performed using this approach. It's most commonly used in oncological surgery. Cryosection is the technical term for this operation.

The quality of frozen section slides is worse than that of formalin-fixed paraffin-embedded tissue processing. While diagnosis can be made in many cases, for more reliable diagnosis, fixed tissue processing is preferred in many cases.

The term "intraoperative consultation" refers to the pathologist's whole intervention, which involves not just frozen sectioning but also gross examination of the specimen, analysis of cytology preparations (such as touch imprints), and aliquoting of the tissue for particular investigations (e.g. molecular pathology techniques, flow cytometry).

The pathologist's report is frequently limited to a "benign" or "malignant" diagnosis and relayed to the operating surgeon over intercom. The pathologist's major goal while operating on a previously confirmed malignancy is to tell the surgeon if the resection margin is clean of residual cancer or if residual cancer is present at the resection margin. The most common way of processing is the bread loafing technique. Margin controlled surgery, on the other hand, can be done with a variety of tissue cutting and mounting techniques.

The cryostat, which is effectively a microtome inside a freezer, is the most important tool for cryosection. The microtome is similar to a high-precision "deli" slicer, capable of cutting slices as thin as 1 micrometre. A typical histology slice is 5 to 10 micrometres thick. The surgical specimen is placed on a met-

ARTICLE HISTORY

Received: 29-Dec-2021, Manuscript No. EJMJIH-22-52320;

Editor assigned: 31-Dec-2021, PreQC No. EJMJIH-22-52320 (PQ);

Reviewed: 14-Jan-2022, QC No. EJMJIH-22-52320;

Revised: 19-Jan-2022, Manuscript No. EJMJIH-22-52320 (R);

Published: 26-Jan-2022.

al tissue disc, which is then frozen quickly at -20°C to -30°C in a chuck. The specimen is implanted in a gel-like medium termed OCT, which is made up of polyethylene glycol and polyvinyl alcohol. This substance has several names and has the same density as frozen tissue when frozen.

Uses

The frozen section approach is mostly used to examine tissue while surgery is being performed. This could be for a variety of reasons. It is a simple method for real-time margin management of a surgical specimen used in Mohs surgery. A sample of the suspected metastasis is sent for cryosection to establish it's identifying if a tumour appears to have metastasized. This will assist the surgeon in determining whether or not the procedure should be continued. Aggressive surgery is usually performed only if the patient has a prospect of being cured. When a tumour has spread, surgery is usually not curative, and the surgeon will opt for a less invasive procedure or no excision at all.

Assuming that a growth has been resected yet it is muddled whether the resection edge is liberated from cancer, an intra-operative meeting is mentioned to survey the need to make a further resection for clear edges. A sentinel node containing tumor tissue prompts a further lymph node dissection, while a benign node will avoid such a procedure.

If surgery is explorative, rapid examination of a lesion might help identify the possible cause of a patient's symptoms. It is important to note, however, that the pathologist is very limited by the poor technical quality of the frozen sections. A final diagnosis is rarely offered intraoperatively.