

Multiple Plexiform Xanthomatous Tumor: A Rare Occurrence in A Young Girl

Kanthilatha Pai¹, Poornima Baliga¹, Ramachandra Lingadakai², Sathish Pai³

*Department of Pathology¹, KMC International Center, Manipal University, India
Departments of Surgery² and Dermatology³, KMC, Manipal University, India*

Received: February 19, 2013

Accepted: March 08, 2013

Published Online: March 18, 2013

DOI: 10.5455/jihp.20130308093821

Corresponding Author:

Kanthilatha Pai,
KMC International center,
Manipal University, India
klpai@yahoo.comy

Keywords: Plexiform, Xanthomatous tumor, female

Abstract

Plexiform Xanthomatous Tumor (PXT) is a rare benign tumor occurring in the dermis and subcutis composed of xanthomatous cells arranged in a distinct plexiform pattern. This condition has been found to occur exclusively in males. A rare occurrence of multiple plexiform xanthomatous tumors in a young female clinically diagnosed as multiple neurofibromatosis is presented. Literature search revealed only one case of PXT reported in female. Hence this case is presented for its rarity.

© 2013 GESDAV

INTRODUCTION

Plexiform xanthomatous tumors are rare tumors that need to be differentiated from reactive lesions and also other tumors with xanthomatous cells. It is sometimes associated with elevated levels of serum cholesterol and triglycerides. We present a rare case of this condition occurring in a young girl and review the literature.

CASE REPORT

A 12- year- old girl presented with multiple swellings over both elbows, posterior aspect of thighs, knuckles, dorsum of feet and sacrum since 2 years. The swellings were initially small in size and gradually increased in size. There was no associated pain, stiffness or fever. On clinical examination, largest swelling measured 5x3 cm and smallest 3x2 cm. All the swellings were non-tender, firm, mobile, not fixed to the overlying skin and joint motility was normal. No pigmentation or cafe-au-lait spots were noted over the skin. X-ray showed soft tissue shadow without any bony changes. 4 of these

lesions were excised with a clinical diagnosis of plexiform neurofibromatosis. There was no history of similar illness in the family. There was no family or personal history of diabetes mellitus, hypercholesterolemia, or hyperlipoproteinemia.

The excised specimen consisted of multiple skin covered tissue masses excised from the elbow, gluteal region, sacrum and foot. The largest mass measured 6x5x4 cm and smallest 3x2x1 cm. Cut surface of the masses showed yellow areas and glistening, whorled areas (Figure 1).

The microscopic sections showed intact, hyperkeratotic epidermis overlying multiple, nodular, plexiform tumors in the dermis and subcutis composed of spindle shaped to xanthomatous cells with abundant, finely vacuolated to foamy cytoplasm, and vesicular nuclei, along with many proliferating capillaries. Also seen focal areas of extracellular fat with cholesterol clefts (Figure 2 and 3)



Figure 1. Excised specimen showing multiple skin covered nodules, with a yellow white soft cut section.

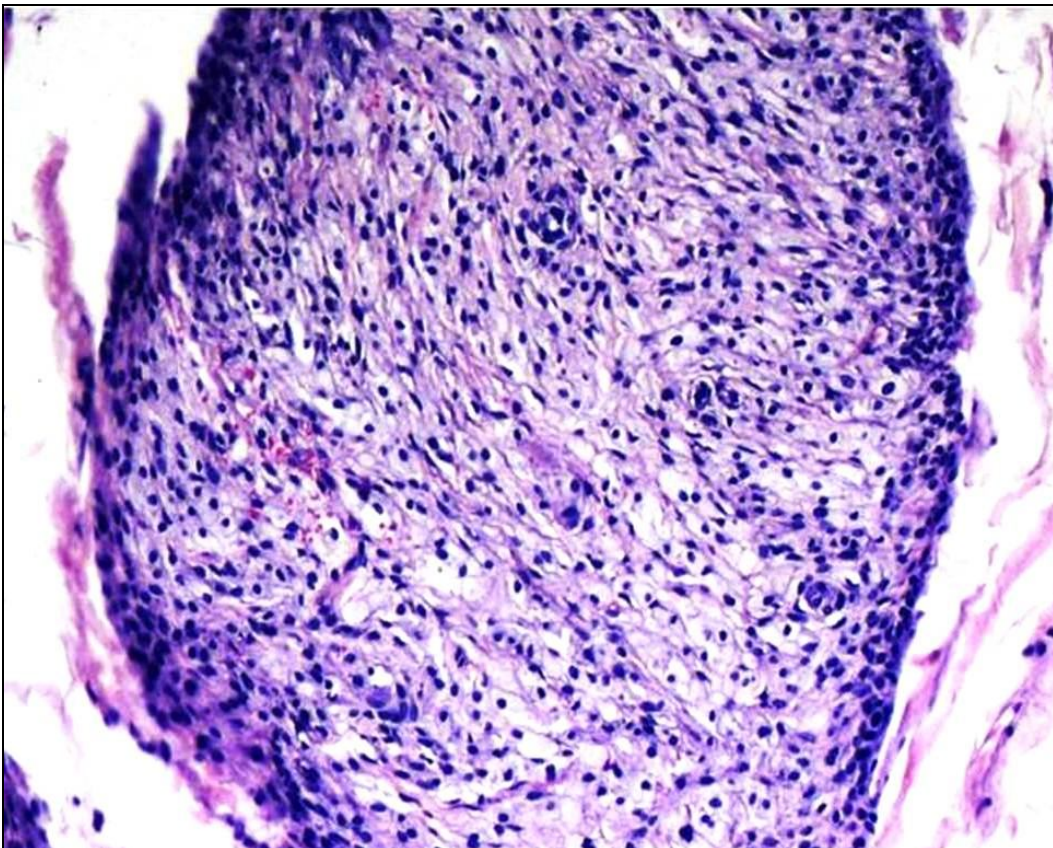


Figure 2. Photomicrograph showing plexiform arrangement of spindle shaped cells with foamy cytoplasm (H&E, x200).

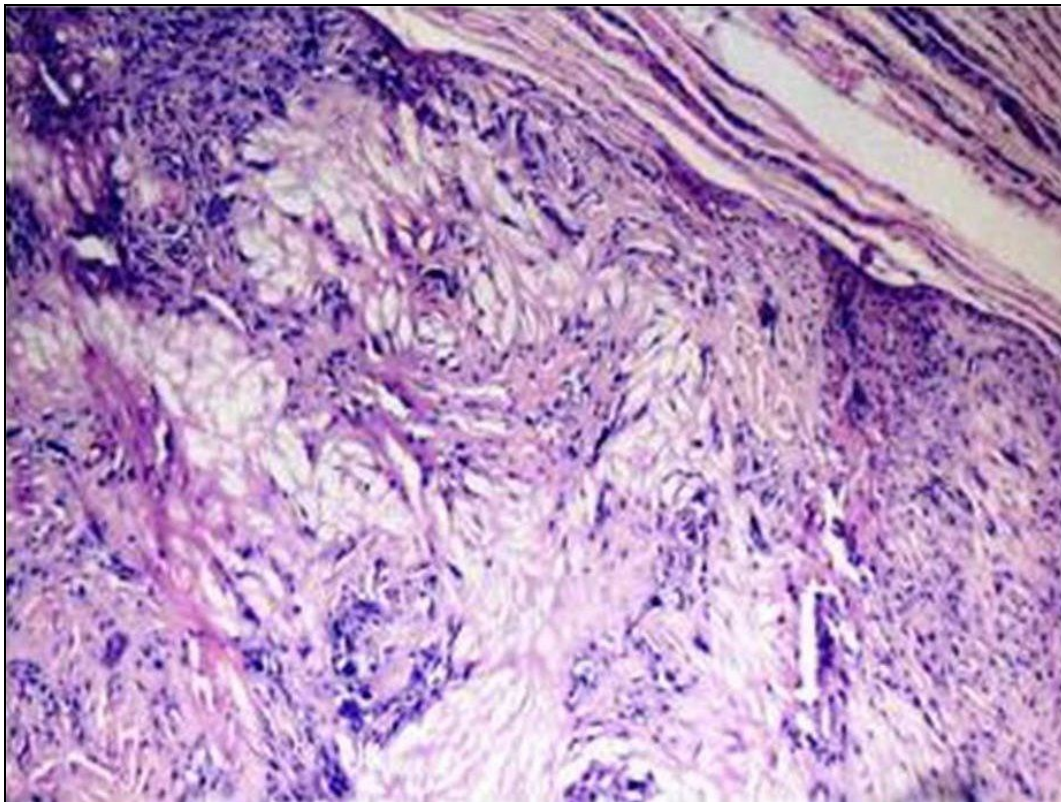


Figure 3. Photomicrograph showing numerous cholesterol clefts among tumor cells (H&E, x200)

We requested for a complete lipid profile for clinical correlation. Lipid profile results showed a markedly elevated triglyceride level of 560 mg / dl, total cholesterol of 260 mg / dl and low density lipoprotein (LDL) of 180 mg/ dl. A histopathological diagnosis of plexiform xanthomatous tumor was made based on microscopic findings and taking the lipid profile into consideration.

DISCUSSION

Plexiform Xanthomatous Tumor (PXT) was described by Michal M in 1994 [1]. Microscopically, these lesions are composed of xanthomatous cells with vague storiform pattern admixed with rare multinucleated giant cells and sparse infiltrate of lymphocytes and plasma cells. A striking feature of these tumors is their exclusive occurrence in men [1]. Men are more susceptible to the occurrence of these lesions even with subclinical levels of hypercholesterolemia and elevated levels of serum triglycerides. Michal M reported 20 cases of PXT in 12 patients, all of whom were male [2]. These tumors can be solitary or multiple and range in size from few millimeters to several centimeters in size. Occurrence of this condition in a female is rarely reported. The other properties include the multiplicity

of these tumors and presence of elevated levels of serum triglycerides and cholesterol in some patients [2].

The tumors share some morphological features with xanthoma, cholesterolotic fibrous histiocytoma, and plexiform fibrohistiocytic tumor and other conditions having xanthomatous component. Local dystrophic xanthomas can develop at the site of trauma or other lesions even in normolipidemic patients [3]. An unusual case of xanthomatous pseudotumour developing as post-chemotherapy phenomenon in a 46 year old woman with breast cancer has been reported [4]. Fibrohistiocytic tumors occur in children and adolescents both in males and females, but histologically rarely show xanthomatous morphology and lack the plexiform arrangement on microscopy.

Plexiform xanthomatous tumor can be easily misdiagnosed and has to be distinguished from plexiform variants of soft tissue lesions such as neurofibroma, benign schwannoma and fibrohistiocytic tumors [5]. Microscopically, neurofibroma and schwannoma can be identified based on the presence of their spindle-celled, non-xanthomatous component. Immunohistochemically, PXT is positive for CD68 and vimentin. Cytokeratins, S-100 protein, CD34,

epithelial membrane antigen, muscle-specific actin, and desmin are negative. Local recurrences may occasionally occur.

The question as to whether PXT is a variant of tuberous and tendinous xanthoma is so far unclear. In contrast to PXT, the latter entity commonly arises in women with typical location on the Achilles tendon [6]. In addition, plexiform growth pattern is not a distinct feature seen in tuberous and tendinous xanthoma. Further study with large series of tuberous and tendinous xanthoma lesions is needed to resolve this question.

To conclude, PXT is a distinct entity with exclusive occurrence in men, with personal/familial hyperlipidemia/hypercholesterolemia in some patients, and relative paucity of inflammation and cholesterol clefts.

REFERENCES

1. Michal M. Plexiform xanthomatous tumor. A report of three cases. *Am J Dermatopathol* 1994; 16: 532-6.
2. Michal M, Fanburg-Smith JC. Plexiform Xanthomatous Tumor. A report of 20 cases in 12 patients. *Am J Surg Pathol* 2002; 26: 1302-11.
3. Mohsin SK, Lee MW, Amin MB, Stoler MH, Eyzaguirre E, Ma CK, Zarbo RJ. Cutaneous Verruciform Xanthoma. A report of five cases investigating the etiology and nature of xanthomatous cells. *Am J Surg Pathol* 1998; 22:479-87.
4. Tan KB, Thamboo TP, Raju GC. Xanthomatous Pseudotumor. An unusual postchemotherapy phenomenon in breast cancer. *Arch Pathol Lab Med* 2003; 127: 739-4.
5. Beham A, Fletcher C D M. Plexiform xanthoma: an unusual variant. *Histopathol* 1991; 19: 565-7
6. Bude RO, Adler RS, Bassett DR. Diagnosis of Achilles tendon xanthoma in patients with heterozygous familial hypercholesterolemia: MR vs sonography. *Am J Roentgenol* 1994, 162: 913-917.

This is an open access article licensed under the terms of the Creative Commons Attribution Non-Commercial License which permits unrestricted, non-commercial use, distribution and reproduction in any medium, provided the work is properly cited.